Home Questions Jobs
Search for researchers, publications, and more
Add new
Overview Stats Comments Citations References (4)
Share
View your saved research
You can access your Saved List at any time in your profile's new Saved List tab.
OK
Citations
Recommendations
Reads
See details

Conference Paper Full-text available

Abstract: Evaluation of vertebral fracture assessment images for the detection of abdominal aortic calcification

June 2017
Conference: All Wales Medical Physics and Clinical Engineering Summer Meeting 16 June 2017 · At: Village Hotel, Swansea, Wales, UK

Karima Elmasri · Yulia Hicks · Xin Yang · Show all 6 authors · William David Evans

Abstract

Dual-energy x-ray absorptiometry (DXA) is an established modality for the assessment of bone mineral density. DXA has also been used for the detection of abdominal aortic calcification (AAC) using lateral images taken for vertebral fracture assessment (VFA). In this phantom study, the capability of VFA for the detection of AAC was investigated. A Perspex phantom of variable width in the range 15-30 cm was used to simulate abdominal soft tissue. Aluminium strips of thickness 0.05-2.0 mm were sandwiched between two halves of the phantom to mimic aortic calcification. VFA images of the phantom were acquired in single-energy mode and analysed by placing regions of interest over the aluminium strip and an adjacent area of Perspex. For each phantom width, the minimum detectable aluminium thickness was assessed visually and related to contrast-to-noise ratio (CNR). Linearity of pixel value with aluminium thickness was tested by linear regression and correlation. Repeatability was measured with five repeated scans for selected phantom configurations. The minimum thickness of aluminium that could be visualised increased with phantom width and varied from 0.05 mm at 15 cm Perspex to 0.5 mm at 30 cm Perspex; the CNR threshold was about 0.03. At all phantom widths, the variation of pixel value with aluminium thickness was strongly linear (r^2>0.98, p<0.001). Repeatability was good with a coefficient of variation of less than 0.04%. The results of the study suggest that under idealised imaging conditions, VFA is capable of detecting small thicknesses of calcification with good linearity and repeatability.

Springer Computer Science Ad
Did you know publishing a book can...?
Connect you with your research community
Accelerate your career
Build your reputation and cement your legacy
Have an idea for a computer science book?
Publishing a book can help connect you with the computer science research community and accelerate your career.
Learn more

Karima, increase the visibility of this article
If your co-authors confirm their authorship, more researchers will find and read this article on ResearchGate.
Rebecca Jane Pettit
Invite co-authors Not now

Related research
Cost effectiveness analysis of using quantitative ultrasound as a selective pre-screen for bone densitometry
Article Full-text available February 2005
Download
View more

Public Full-texts 2 Private Full-text 1
Elmasri Abstract.pdf
Content uploaded by William David Evans Author content
Content may be subject to copyright.

Page 1

Evaluation of vertebral fracture assessment images for the detection of abdominal aortic calcification

Karima Elmasri, Research Student
Yulia Hicks, Senior Lecturer
Xin Yang, Lecturer
Xianfang Sun, Lecturer
Rebecca Pettit, Principal Clinical Scientist
William Evans, Consultant Clinical Scientist
Cardiff University

ElmasriKM@cardiff.ac.uk

Dual-energy x-ray absorptiometry (DXA) is an established modality for the assessment of bone mineral density [1]. DXA has also been used for the detection of abdominal aortic calcification (AAC) using lateral images taken for vertebral fracture assessment (VFA) [2]. In this phantom study, the capability of VFA for the detection of AAC was investigated.

A Perspex phantom of variable width in the range 15-30 cm was used to simulate abdominal soft tissue. Aluminium strips of thickness 0.05-2.0 mm were sandwiched between two halves of the phantom to mimic aortic calcification [3,4]. VFA images of the phantom were acquired in single-energy mode and analysed by placing regions of interest over the aluminium strip and an adjacent area of Perspex. For each phantom width, the minimum detectable aluminium thickness was assessed visually and related to contrast-to-noise ratio (CNR). Linearity of pixel value with aluminium thickness was tested by linear regression and correlation. Repeatability was measured with five repeated scans for selected phantom configurations.

The minimum thickness of aluminium that could be visualised increased with phantom width and varied from 0.05 mm at 15 cm Perspex to 0.5 mm at 30 cm Perspex; the CNR threshold was about 0.03. At all phantom widths, the variation of pixel value with aluminium thickness was strongly linear (r^2>0.98, p<0.001). Repeatability was good with a coefficient of variation of less than 0.04%.

The results of the study suggest that under idealised imaging conditions, VFA is capable of detecting small thicknesses of calcification with good linearity and repeatability.

References:

[1] A El Maghraoui and C Roux. DXA scanning in clinical practice. *Quarterly Journal of Medicine* (2008); **101**: 605–617.

[2] K Elmasri, Y Hicks, X Yang, X Sun, R J Pettit and W D Evans. Automatic detection and quantification of abdominal aortic calcification in dual energy x-ray absorptiometry. *Procedia Computer Science* (2016); **96**: 1011–1021.

[3] L A Fitzpatrick, A Severson, W D Edwards and R T Ingram. Diffuse calcification in human coronary arteries: association of osteopontin with atherosclerosis. *Journal of Clinical Investigation* (1994); **94**: 1597–1604.

[4] L M Warren, A Mackenzie, D R Dance and K C Young. Comparison of the x-ray attenuation properties of breast calcifications, aluminium, hydroxyapatite and calcium oxalate. *Physics in Medicine and Biology* (2013); **58**: N103-N113.

View Full-text

Similar research

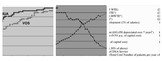

Cost effectiveness analysis of using quantitative ultrasound as a selective pre-screen for bone densitometry
Article Full-text available February 2005 · Technology and health care: official jo...
Victor Man Fai Sim · Michael D Stone · Ceri J Phillips · [...] · William David Evans
It has been suggested that quantitative ultrasound (QUS) could be used as a selective population pre-screen, to maximise the cost effectiveness of referral for dual energy X-ray absorptiometry (DXA) assessment of bone mineral density (BMD). We set out to...
68 Reads · 18 Citations
Download Recommend Follow Share

Hidden Depletion of Fat-Free Mass and Bone Mineral Density in Adults With Cystic Fibrosis
Article Full-text available December 2003 · Chest
Alina A Ionescu · William David Evans · Rebecca Jane Pettit · [...] · Dennis J Shale
Weight loss is associated with reduced survival in patients with cystic fibrosis (CF). We hypothesized that some adult patients with a normal body mass index (BMI) have evidence of hidden fat-free mass (FFM) and bone mineral density (BMD) depletion th...
25 Reads · 67 Citations
Download Recommend Follow Share

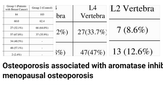

Osteoporosis associated with aromatase inhibitors is different from post-menopausal osteoporosis
Article Full-text available December 2012
Hasan Mutlu · Tuncay Aslan · Güler Silov · [...] · Abdullah Büyükçelik
osteoporosis associated with aromatase inhibitors is different from post-menopausal osteoporosis. Adv Lab Med Int. 2012; 3(1) 1 - 5. ABSTRACT Osteoporotic effects are one of the known side effects of aromatase inhibitors that are used in the treatment ...
71 Reads · 1 Citation
Download Recommend Follow Share

Abstract: Bone mineral density in hypothyroid and treated hyper-thyroid females on thyroxine
Conference Paper Full-text available November 1996 · Nuclear Medicine Comm...
Rebecca Jane Pettit · William David Evans · Declan P. Coleman · [...] · John H Lazarus
It has been established that hyperthyroidism is associated with reduced bone mineral density (BMD), but it is unclear whether thyroxine therapy is also accompanied by low BMD. The aim of this study was to compare lumbar spine and femoral neck bone...
14 Reads
Download Recommend Follow Share



The Ratio of Anterior and Posterior Vertebral Heights Reinforces the Utility of DXA in Assessment of Vertebrae Strength
Article Full-text available May 2014 · Calcified Tissue International
Grzegorz Taton · Eugeniusz Rokita · Mariusz Korkosz · Andrzej Wróbel
The objective of the study was to introduce a new parameter describing bone strength with greater precision than the widely used antero-posterior DXA (dual-energy X-ray absorptiometry), which measures areal bone mineral density (aBMD). The adjusted...
58 Reads · 9 Citations
Download Recommend Follow Share

View more related research

NAWA Poland Ad
THE ULAM NAWA PROGRAMME
A UNIQUE CHANCE TO DO YOUR OWN RESEARCH PROJECT
Achieve your aims with the NAWA fellowship
Are you thinking about the next step in your research career? Submit your application under the Ulam NAWA Programme!
Find out more

© 2008-2021 ResearchGate GmbH. All rights reserved. About us · News · Careers · Help Center · Advertising · Recruiting | Terms · Privacy · Copyright · Imprint
App Store